



# Al Nile Hospital

## مستشفى النيل

Surname/Forenames: **GURVINDER SINGH**

PLEASE COMPLETE YOUR PERSONAL DETAILS IN BLOCK CAPITALS

Nationality: **INDIAN**

Mobile No: **98263396**

Home/Leave Address:

Company Number:

Reference Indicator:

### Personal Details

A  Male  Female

Married  Single  Separated / Divorced / Widow(er)

Home/Leave Address:

Relationship to employee:  Wife  Son  Daughter No. of children: **7**

Reason for Examination (tick as appropriate)

Periodic Medical Examination  Final / Retirement  Other Reason

### Employee only

B Present Job and Location:

**DRIVER**

Next Job and Location:

Are you a registered person with special needs?

Do you belong to any Medical Insurance Scheme?

Previous Medical History: All important medical events should be listed and dated at every medical examination. To be completed (together with the interviewing Nurses or Doctor who will be able to help by referring to your notes).

Please answer the following questions and tick 'N' (no) or 'Y' (yes) in the columns. If 'Y' please describe

	N	Y	Description
Have you since your last medical been treated by your family doctor or (hospital) for significant (major) ailments?		<input checked="" type="checkbox"/>	
1 Ear, nose, eye or throat problems		<input checked="" type="checkbox"/>	
2 Chest problems like asthma, bronchitis, other bad cough		<input checked="" type="checkbox"/>	
3 Heart abnormality, chest pains		<input checked="" type="checkbox"/>	
4 Abdominal pains, abnormal bowel motions		<input checked="" type="checkbox"/>	
5 Urinary problems (kidney disease, menstrual disorder)		<input checked="" type="checkbox"/>	
6 Skin troubles or allergies		<input checked="" type="checkbox"/>	
7 Epileptic fits, dizzy spells or migraine		<input checked="" type="checkbox"/>	
8 History of mental illness, depression anxiety		<input checked="" type="checkbox"/>	
9 Diabetes, thyroid disease		<input checked="" type="checkbox"/>	
10 Blood disorder e.g., anaemia, blood cancer e.g., leukaemia		<input checked="" type="checkbox"/>	
11 Any history of accidents or fractures		<input checked="" type="checkbox"/>	
12 Have you had any serious allergies		<input checked="" type="checkbox"/>	
13 Do any dependants have a significant ongoing illness?		<input checked="" type="checkbox"/>	
14 Any family history of cancers		<input checked="" type="checkbox"/>	
Do you take any regular medicines, or have you taken in the past?		<input checked="" type="checkbox"/>	
Do you smoke? If yes, what and how much each day?		<input checked="" type="checkbox"/>	
Do you drink alcohol? If yes, what is your average weekly intake?		<input checked="" type="checkbox"/>	
Have you ever taken illicit/recreational drugs?		<input checked="" type="checkbox"/>	
Are you doing regular sports or physical activities?		<input checked="" type="checkbox"/>	

**STATEMENT** I have read the above questions and the above answers are correct and no information concerning my present or past state of health has been withheld. I understand and agree that this form will be held as a confidential record by the concerned medical institute and may be copied (by paper or secure electronic transmission) to PDO the Occupational Health Services for the purpose of Health Surveillance and other Occupational Health review.

Date: **9/08/20**

Signature of Applicant:

*Gurinder*





# Al Nile Hospital مستشفى النيل

FOR COMPLETION BY EXAMINING PHYSICIAN

Further details of medical history and recreational activities

N = Normal, A = Abnormal (unless described) **PHYSICAL EXAMINATION**

N	1. Eyes & Ears	
N	2. ENT	
N	3. Teeth & Mouth	dental (carie)
N	4. Lungs & Chest	
N	5. Cardiovascular System	
N	6. Abdo. Viscera	
N	7. Hemat. Onites	
N	8. Anus & Rectum	
N	9. Genito-urinary	
N	10. Extremities	
N	11. Musculo-skeletal	
N	12. Skin & Varicose Vns	
N	13. C.N.S	

HEIGHT cm	WEIGHT kg	BMI	B.P.	PULSE /mins.	HEARING L Normal R Normal	VISION Uncorrected Corrected	DISTANT R L	NEAR R L
173cm	84kg	28.7	150/90	114			6/6 6/6	6/6 6/6
							6/6 6/6	6/6 6/6

N	A	LABORATORY AND OTHER SPECIAL INVESTIGATIONS	N	A
N		High WBC without left shift with normal ESR	N	7. Audiogram
N				8. Lung Function
N			N	9. Chest X-Ray
N			A	10. ECG
				11. CVS risk for 40 yrs. & above
				12. HIV, Hepatitis screening

OTHER FINDINGS (Physique, scars, disabilities, mental stability including behaviour, etc.)

ECG: Sinus Tachycardia - left axis deviation - incomplete RBBB  
Signs of suspected right ventricular hypertrophy - High BP.

ASSESSMENT AND RECOMMENDATIONS:

FIT ALL AREAS  FIT WITH RESTRICTION  TEMPORARY UNFIT  UNFIT

Date: 11/06/2022 Name (Block Capitals): Dr. Ali Shassah Signature:

REVIEW/CONSULTATION

Date: Name (Block Capitals): Dr. Ali Shassah Risk/Anxiety





Employee Data	DATE 9/08/25
NAME: GURVINDER SINGH	Company: TRUCK MAN
ID No. 68785161	Occupation: DRIVER

### The Epworth Sleepiness Scale

How likely are you to doze off or fall asleep in the following situations? You should rate your chances of dozing off, not just feeling tired. Even if you have not done some of these things recently try to determine how they would have affected you. For each situation, decide whether or not you would have:

- No chance of dozing =0
- Slight chance of dozing =1
- Moderate chance of dozing =2
- High chance of dozing =3

Write down the number corresponding to your choice in the right-hand column. Total your score below.

Situation	Chance of Dozing
Sitting and reading	• 0
Watching TV	• 0
Sitting inactive in a public place (e.g., a theater or a meeting)	• 0
As a passenger in a car for an hour without a break	• 1
Lying down to rest in the afternoon when circumstances permit	• 2
Sitting and talking to someone	• 0
Sitting quietly after a lunch without alcohol	• 2
In a car, while stopped for a few minutes in traffic	• 0

Total Score =

5

#### Analyze Your Score

##### Interpretation:

- 0-7: It is unlikely that you are abnormally sleepy.
- 8-9: You have an average amount of daytime sleepiness.
- 10-15: You may be excessively sleepy depending on the situation. You may want to consider seeking medical attention.
- 16-24: You are excessively sleepy and should consider seeking medical attention.

Reference: Johns MW. A new method for measuring daytime sleepiness: The Epworth Sleepiness Scale.





### Fitness to Work Certificate

Employee Data		Date	9/08/25
Last Name		First Name	GURVINDER
I.D No.	68785161	Age	434
Occupation		DRIVER	
Type of Medical Evaluation <span style="float: right;">Mark those applying</span>			
A1 Aircraft refueling	<input type="checkbox"/>	A6 Emergency response team work	<input type="checkbox"/>
A2 Breathing apparatus	<input type="checkbox"/>	A7 Professional driving	<input type="checkbox"/>
A3 Business traveler	<input type="checkbox"/>	A8 Remote location work	<input type="checkbox"/>
A4 Catering and food preparation	<input type="checkbox"/>	A9 Transfers- group A country	<input type="checkbox"/>
A5 Crane or forklift driving	<input type="checkbox"/>	A10 Transfers-group B country	<input type="checkbox"/>

Health Advisor statement The Above named person has been examined according to the statements laid down in "Protocols and Guidance Notes on the Medical Evaluation of Fitness to Work". At this time their fitness to work status for the above tasks is as follows

Fit with no restrictions	<input checked="" type="checkbox"/>	<b>FIT</b>
Fit with following restrictions	<input type="checkbox"/>	
The employee is fit for above work but should avoid the following tasks		
Work near moving machinery or sharp edges	<input type="checkbox"/>	Operate motor vehicles, forklifts or heavy machinery
Working at height	<input type="checkbox"/>	Use a respirator
Pull push carry weight over Kg	<input type="checkbox"/>	Repetitive twisting of valves or wrenches
Ascend/descend ladders or stairs	<input type="checkbox"/>	Flying
Other(Specity)		
These restrictions are permanent		
These restrictions are temporary until		(date)
Temporary Unfit until		(date)
Permanently Unfit		

Date	11/08/2025	Signature		Print Name	
------	------------	-----------	--	------------	--



## GURVINDER SINGH

Estimated 10-year Global CVD Risk: 7.9%

Risk Category: Low Risk

Estimated Vascular Age: 51 Years

1. Gender? — Male
2. Age? — 40-44
3. Total Cholesterol? — 5.16-6.19 mmol/L
4. HDL? — 1.17-1.29 mmol/L
5. Systolic Blood Pressure? — 140-149 mmHg
6. On Medication for Hypertension? — No
7. Smoker? — No
8. Diabetic? — No
9. Known Vascular Disease (CAD, PVD, Stroke)? — No



The image shows a handwritten signature in blue ink, which appears to be 'Gurvinder Singh'. Below the signature is a rectangular stamp. The stamp contains the following text: 'GURVINDER SINGH' in large letters, 'MD' in smaller letters, 'MBBS, DNB (General Medicine)', 'GURVINDER SINGH', 'MD, DNB (General Medicine)', and '1985-1995'.



## Medical Report

Patient Name: GURVINDER SINGH		Date: 09/08/2025 11:58:21
File No: 25013162	Age/Gender: 43y 8m 23d / M	Nationality: India
Payer Name: --		Doctor: Dr. Bassel Ali Al Ratel
Insurance Card No:	ID Card No: 68785161	Phone: 98263396

### Vitals:-

Temperature	BP (SBP/DBP)	Pulse Rate	Respiratory Rate	Weight	Height	SPo2	RBS:	Pain Level	Abdominal Circumference	Head Circumference	CVP	Body Mass Index
36.4° C	150 / 90 mmHG	114 bpm	0bpm	84.0kg	173.0 cm	0 SPO2		0	0.0	0.0		28.066424

### Chief Complaints:-

referred by the GP for cardiac evaluation

### Patient History:-

the patient was referred by the GP for evaluation of an ECG abnormalities and elevated BP readings he denies any chest pain, exertional symptoms, palpitation, dizziness ECG: LAD with borderline RVH SR: RES-, CV-, GU- PMH: unremarkable PE: RESP and CVS are WNL, no pedal edema Social.H: EX-smoker, quitte 8 years ago, nonalcoholic FH: unremarkable

### Radiology Report:-

CXR: mild reticular infiltrates in the lower lung fields with increased bronchial markings Echocardiography: poor window Left ventricle: Normal size and function, EF 70%, no regional wall motion abnormalities. (eyeballing) Left atrium: Normal size. Mitral valve: Normal structure and flow, E/A= 1.8. Aortic valve: Three leaflets, normal flow and structure. Ascending Aorta: normal structure without dilatation Right ventricle: Normal size, walls, and function. Right atrium: Normal size. Tricuspid valve: Mild regurgitation, PASP=20 mmHg, normal structure. Pulmonary valve: Normal structure and flow. TAPSE: 24 mm. Both RVOT and LVOT are WNL Pericardium: Dry. Conclusion: Normal echocardiographic study

### Management Plan:-

the patient has anxiety and white-coat hypertension, I will commence him on Inderal 10mg TD for 1 week then reevaluate him the patient is low risk for ASCVD

### Investigations:-

No.	Internal Code	Name
1		CHEST X-RAY
2		CONVENTIONAL ECHOCARDIOGRAPHY

Dr. Bassel Ali Al Ratel





**Al Nile**  
**Medical Complex**  
**مجمع النيل الطبي**

P.O.BOX:300, POSTAL CODE - 611 NIZWA, SULTANATE OF OMAN C.R.NO.1128642  
PH : 25426665, 25426228 \ WHATSAPP:94146648  
Instagram:[https://www.instagram.com/alnile\\_medical](https://www.instagram.com/alnile_medical)

Licence Number: 19770

2025-08-11 09:51:15

\*\*End of Report\*\*





Patient Name: GURVINDER SINGH  
File No: 25013162  
Age: 43y 8m 22d  
Gender: Male  
Nationality: India



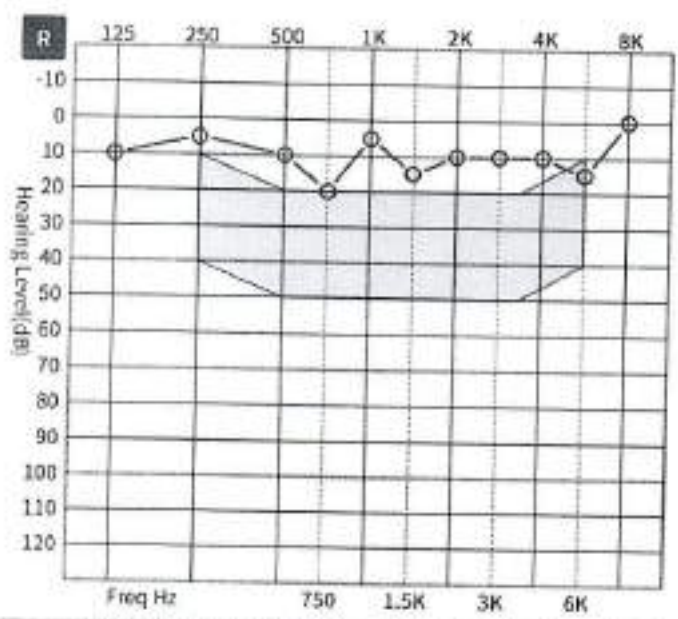
# PTA Test Report

ID:25013162

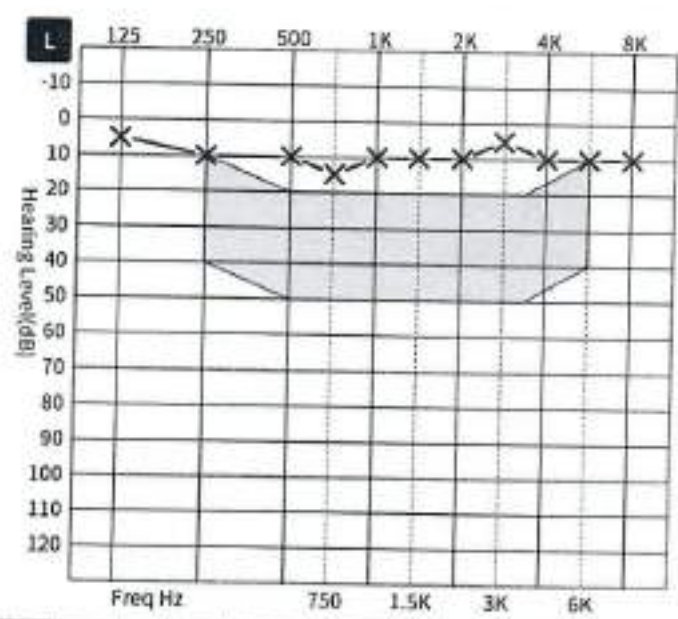
Name:GURUVINDER SINGH

Gender:Male

Age:43Y



	125	250	500	750	1K	1.5K	2K	3K	4K	6K	8K
Air	10	5	10	20	5	15	10	10	10	15	0
Bone											



	125	250	500	750	1K	1.5K	2K	3K	4K	6K	8K
Air	5	10	10	15	10	10	10	5	10	10	10
Bone											

Test Result: BILATERAL HEARING SENSITIVITY WITHIN NORMAL LIMITS



Test Date:2025-08-08 22:18

Printing Date:2025-08-08 22:18

Examiner: \_\_\_\_\_



2025-08-09 10:04:04  
 Name : CURVINDER SINGH  
 Sex : Age : 0  
 Section: DR. ALI  
 RoomID:  
 BedID:  
 ID:  
 Operator: MAYA  
 chx:

Data for reference only:

HR : 109 bpm  
 PR Interval : 158 ms  
 P Duration : 120 ms  
 QRS Duration : 109 ms  
 T Duration : 173 ms  
 QT/QTc : 331/446 ms  
 P/QRS/T Axis deg : 73.5/-30.5/63.4  
 R(V5)/S(V1) mV : 0.49/0.13  
 R(V5)+S(V1) mV : 0.61

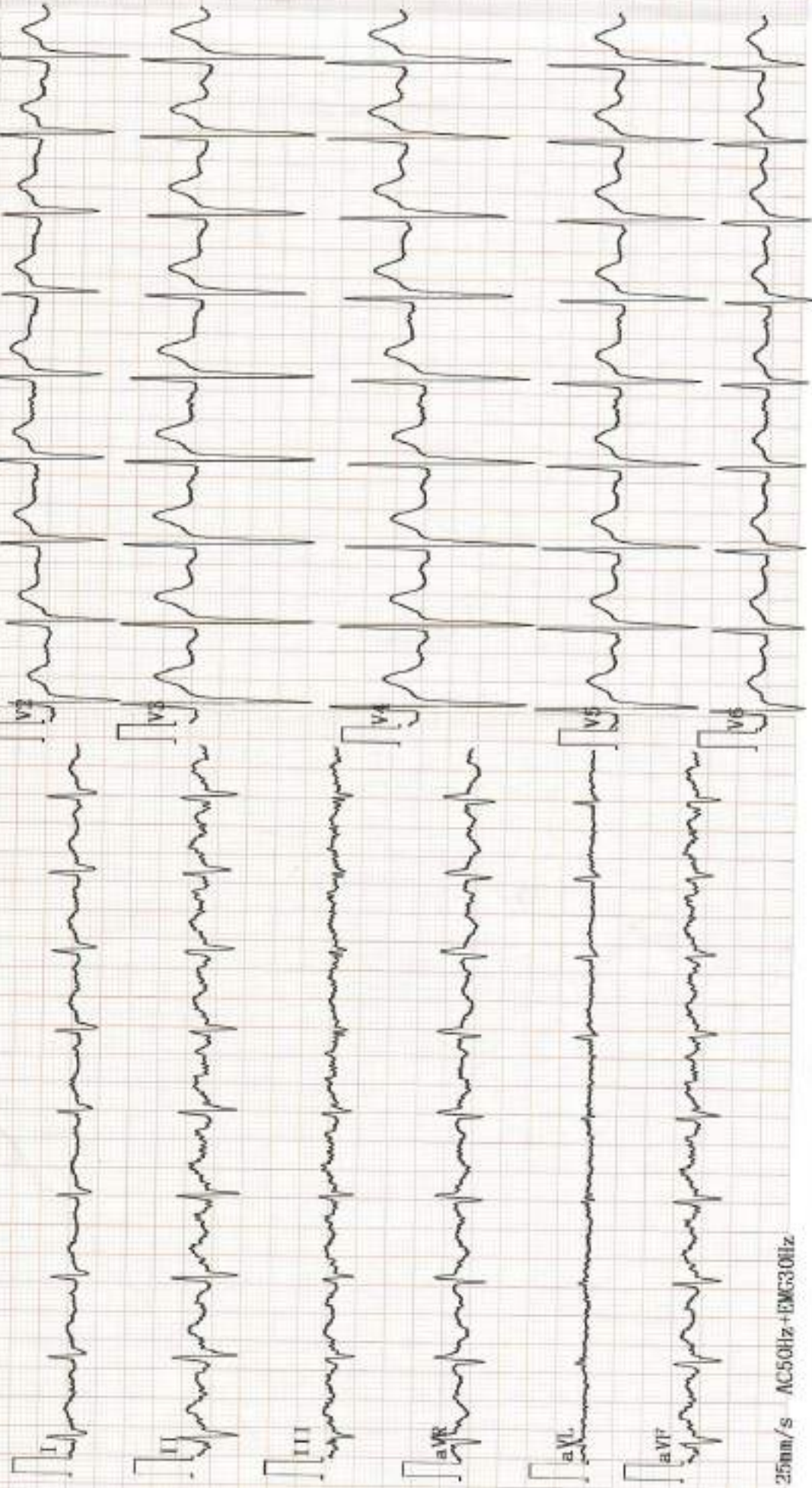
<< Conclusions >>

Sinus mode Tachycardia;  
 Severity Left axis deviation;

\*\*Report need physician confirm\*\*

AUTO 10mm/mV

Physician:





## Lab Report

Patient Name:	GURVINDER SINGH	Date:	09/08/2025 09:08:34
File No:	25013162	Age/Gender:	43y 8m 21d / M
Payer Name:		Sid No:	Bill#32290
Insurance Card No:	--	Collection Date & Time:	09/08/2025 08:52:37
Doctor:	Dr. Ali Mohammad Ghassah	Received Date & Time:	09/08/2025 09:08:34
Billing Time:	09/08/2025 08:40:04	Reported Date & Time:	09/08/2025 09:28:57
	Mobile: 98263396	Id Card No.:	68785161

Test Name	Result	Biological Reference
BLOOD SUGAR FASTING	5.55 mmol/m	3.3-6.1
CHOLESTEROL	214.9 mg/dl	< 200.0
HDL CHOLESTEROL	49.9 mg/dl	40.0-60.0
LDL CHOLESTEROL	124.0 mg/dl	< 150.0
TRIGLYCERIDE	203.0 mg/dl	40.0-160.0
UREA	15.9 mg/dl	15.0-45.0
CREATININE	1.25 mg/dl	0.7-1.4
URIC ACID	3.7 mg/dl	3.4-7.0
ALKALINE PHOSPHATASE	84.0 U/L	35.0-104.0
SGPT	61.1 U/L	< 41.0
SGOT	27.4 U/L	< 40.0
BILIRUBIN TOTAL	0.466 mg/dl	< 1.1
TOTAL PROTEIN	8.2 g/dl	6.6-8.7
ALBUMIN	4.59 g/dl	3.5-5.2
ESR(AUTOMATED)	4.0 mm/hr	< 15.0
Complete Blood Count		
Haemoglobin	15.3 mg/dl	13.0-18.0
Total leucocyte count	15,420.0 Cells / Cumm	3,999.0-11,000.0
Differential count		
Neutrophil	61.7 %	40.0-75.0
Lymphocytes	29.1 %	15.0-45.0
Eosinophils	0.2 %	1.0-6.0
Monocyte	8.4 %	2.0-8.0
Basophils	0.4 %	< 1.0
Packed cell volum	45.3 %	< 54.0
RBC count	5.03 millions/mm	4.5-5.5
MCV	90.0 fl	81.8-95.5
MCH	30.5 pg	27.0-32.3
MCHC	33.8 g/dl	32.4-35.0
Platelet count	283,000.0 Cumm	150,000.0-400,000.0
RDW-CV	12.9 %	11.0-16.0
RDW-SD	42.5 fl	35.0-56.0

URINE ANALYSIS





**Al Nile**  
**Medical Complex**  
**مجمع النيل الطبي**

P.O.BOX:300, POSTAL CODE - 611 NIZWA, SULTANATE OF OMAN C.R.NO.1128642  
PH : 25426665, 25426228 \ WHATSAPP:94146648  
Instagram:https://www.instagram.com/alnile\_medical

Test Name	Result	Biological Reference
Color	Pale Yellow	-
Transparency	Clear	-
Specific Gravity	1.01	-
PH	Alkaline	-
Glucose	NIL	-
Acetone	NIL	-
Bilirubin	NIL	-
Blood	NIL	-
Urobilinogen	NIL	-
Protein	NIL	-
Nitrate	NIL	-
Leukocyte	NIL	-
Pus cells	1-2	-
Erythrocytes	0-1	-
Squamous Epithelial Cell	Few	-
Crystal	NIL	-
Cast	NIL	-
Bacteria	NIL	-
Others	NIL	-

2025-08-09 09:32:38

**\*\*End of Report\*\***

Technician: Hajar Mohammed  
Hussin Mousa  
License No: 9245





*Patient Name: GURVINDER SINGH*  
*Prof. Dr. Dear Colleague*  
*Date: 9 August 2025*  
*Examination: CHEST X-RAY (PA VIEW)*

### **REPORT**

- *Both lung fields are clear with no obvious focal or diffuse parenchymal or interstitial lesion.*
- *Normal appearance of Aortic shadow.*
- *Accentuated both broncho-vascular markings .*
- *Maintained cardio-thoracic ratio.*
- *No obvious hilar or mediastinal mass lesion.*
- *Costo-phrenic & cardio-phrenic pleural angles are free.*
- *Bony framework & soft tissue shadows are within normal limits.*



**MUCH OBLIGED,**  
**Dr. Nesreen Ghazy**  
**Lic.No: 26650**

